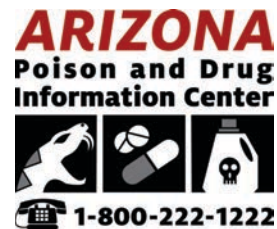

# NEWS FROM THE PIT

Arizona Poison and Drug Information Center



## Thick and Thin

Treatment of thrombosis in snake envenomation

By Tyler Hoelscher, MD

I live very far from water. I've called both the Sonoran and the Mojave deserts my home, yet in researching material for this article, I've found myself wading very deeply into the ocean of uncertainty. Back in medical school I was taught the concept of Evidence-Based Medicine, the practice of guiding treatment based upon well-conducted studies. Gone are the days when we relied solely on the wisdom of the ancients and the opinions of practiced experts. In fact, there exists a hierarchy of evidence, usually portrayed as a pyramid. The peak of this pyramid consists of meta-analyses, studies assembling multiple well-conducted trials into a thoroughly researched conclusion to guide medical practice. The base of this pyramid is made up of expert opinions, not backed up by actual research.

In trying to explain how to treat blood clots in patients with snakebites, I learned that the evidence pyramid actually has a basement of even less-understood medical practice made up of assumptions about physiology, pathology and educated guesses in the near-complete absence of evidence. What I'm saying here is that this entire article needs to be taken with a massive grain of salt. The things I will be explaining today are very rare, potentially very dangerous, and also nearly impossible to study, which is why instead of my introduction consisting of an interesting case or a piece of relevant history, I'm writing a very long disclaimer. There you go, consider yourselves disclaimed.

## NEWSLETTER HIGHLIGHTS

Thick and Thin

# Thick and Thin

Continued from page 1

Alright, now what I'm writing about today is the treatment of thrombosis in snake envenomation. When I use the term thrombosis today I'm primarily going to be describing blood clots in fairly large vessels. This is a separate entity from thrombotic microangiopathy, which we discussed in the VICC article last month. As we've previously explained, hemotoxic snake venom has both anticoagulant and procoagulant properties, and usually the anticoagulant side wins out, which results in bleeding.


More rarely does the venom cause enough microscopic clots to cause TMA, and even more rarely than that does the venom produce clots large enough to block major blood vessels. Because it is so rare, it hasn't really been studied. The only way to do so would be to find enough people prone to blood clots and then convince them to get bitten by snakes so we can experiment on them, but I've been told this may be somewhat ethically questionable.

Now as always, we have to understand some pathophysiology behind blood clotting before we can get into how a snake envenomation complicates things. First to clarify terms, a thrombus is a clot within a blood vessel, thrombosis is the development of such a clot, and embolism is when a piece of that clot is then thrown down the bloodstream, blocking blood flow remote from the initial clot. Now, these are distinct from the concept of atherosclerosis, which is the buildup of fatty plaques within a blood vessel, which risk rupturing and causing rapid thrombosis and blood vessel occlusion.

This is the classic cause of heart attacks, and plays a role in other vascular disorders, but as far as we can tell, snake venom does not significantly impact atherosclerotic vessels, and this article will primarily be discussing thrombosis and embolism unrelated to atherosclerosis. It is worth remembering that any patient with significant plaques in their blood vessels are at increased risk of many of these thrombotic and embolic complications.



**As far as we can tell, snake venom does not significantly impact atherosclerotic vessels.**



# Thick and Thin

Continued from page 2

In medical school we're taught about Virchow's Triad; that is, three elements that greatly increase the risk of thrombosis. These are endothelial disruption, stasis, and hypercoagulability. Endothelial disruption refers to injury to the inner layer of the blood vessels resulting in exposure of proteins that activate the clotting cascade. Stasis refers to blood slowing or not moving within blood vessels, and hypercoagulability refers to some external cause for the blood to coagulate more easily, such as excess estrogen or inherent genetic disorders. Combine these three situations and you've got yourself a recipe for a clot. Most patients tend to be more likely to bleed than to develop a clot. However, we still have a patient who has had disruption of the endothelium via the snakebite, and then in the hospital patients spend most of their day lying in bed, so we have stasis as well, two of the three points of Virchow's Triad.

Another group of patients worth bringing up are the people who are chronically on a blood thinner for conditions like atrial fibrillation or mechanical heart valves. These conditions place them at an inherently high risk of developing a blood clot, which could end up resulting in a stroke. After a snakebite, these patients will typically have their blood thinner withheld until initial control of the envenomation has been obtained. For that period of time, they will still have some risk of a clot. Given the coagulopathy caused by our snakes, this is a reasonable thing to do, however we must be prepared to deal with the risk of thrombosis in these patients.

Blood clots cause many different problems, largely stemming from their ability to block vessels and prevent blood from reaching its target tissue. In the brain this is called a stroke, in the lungs this is called a pulmonary embolism, and in the intestines it's called acute mesenteric ischemia.

Most commonly these clots simply form in a vein, usually in the leg, which is called a deep-vein-thrombosis (DVT). DVT is the most common thrombotic condition in the hospital, so much so that hospitalized patients almost always receive mild anticoagulation or mechanical devices to prevent them from developing. However, on their own, DVTs are not particularly harmful.

Usually a DVT sits in a leg and causes some pain and swelling, not a big deal. The danger of these clots is that they don't necessarily stay in the leg, they tend to get dislodged and thrown into the venous bloodstream, eventually landing in the lungs and causing a pulmonary embolism. Clots can also form within the heart, usually when there is some type of impaired heart motion, whether from abnormal rhythms or injured heart muscle. These clots then get thrown into the arterial bloodstream, where they risk causing strokes in the brain, mesenteric ischemia in the gut, limb ischemia in an arm or leg, or other issues.



*Most patients tend to be more likely to bleed than to develop a clot.*



## Thick and Thin

Continued from page 3

These illnesses are extremely well researched and we in medicine are fairly confident in treating them. The mainstays of treatment consist of thrombolysis, thrombectomy, and anticoagulation. Unfortunately, all of these treatments present their own risks, and if the patient has been envenomated by a snake as well, we are now walking a very narrow tightrope between clotting and bleeding.

Thrombolysis involves giving a medication that actively dissolves blood clots throughout the entire body. There are a few different thrombolytic medications, but the most common is Alteplase, or tPA. Alteplase is an enzyme that broadly activates the body's naturally existing clot-dissolving enzyme, called plasmin. This Tissue Plasminogen Activator (tPA) exists in the human body normally, and functions to help dissolve clots naturally. When tPA is given as a medication, we use doses much higher than the physiologic norm, which can rapidly dissolve clots throughout the body. The main use of tPA as a medication is in stroke, massive pulmonary embolism, and heart attacks, when an angiography suite for stenting is unavailable. This is a somewhat controversial drug that can be risky to use because if you dissolve clots, patients tend to bleed. The story of a patient having a stroke, then being treated with tPA, and afterwards developing a fatal bleed in their brain, is one that we are all too familiar with.

The next treatment option I will discuss is thrombectomy, which is the mechanical removal of the clot from the body. This is currently a very hot area of research. Usually this procedure is done by an interventional radiologist, a type of wizard who does a radiology residency and then extra training to learn how to snake wires and sheaths throughout the body to work some magic. Thrombectomy usually involves inserting a wire through a large vessel in the groin and then following that vessel to the site of the clot where a sheath is deployed, and then either a stent-like retriever or a suction catheter is deployed to pull the clot straight out of the vessel. Thrombectomy can only be used for relatively large clots that can be seen on vascular imaging, but when you can use it, it's truly a lifesaver without nearly as many risks as thrombolysis.

Anticoagulation is the final treatment option, which is basically the administration of a medicine that prevents the body from forming more clots. There are several blood thinning medications that we use to either block certain elements of the coagulation cascade, or to activate antithrombin, an enzyme which then inactivates those pesky coagulation factors. There are several of these medications, some can be taken by mouth, others are given as shots or IV drips, and if needed, there are several different reversal agents to use if the patient develops bleeding while on an anticoagulant.



**Treatment will revolve around the balance between bleeding and clotting.**



## Thick and Thin

Continued from page 4

Anticoagulation is a mainstay of treatment for virtually every thrombosis, but it doesn't actively remove any clots in the body. Instead, it allows the body's own enzymes to slowly break clots down. Sometimes this is all you need, but in cases where an organ or limb is being strangled by an occlusive clot, anticoagulation alone is far too slow. The threatened tissue will be long dead before the clot dissolves, which is where thrombolytics and thrombectomy come in.

So, putting all of this together, how do we approach the treatment of a snake bitten patient who also develops a thrombosis? First of all, we are now formally stepping into that deep ocean of uncertainty I mentioned before. Research here is almost nonexistent and few well-supported conclusions can be made. Every one of these patients needs to be evaluated on a case-by-case basis. Furthermore, this is not the time for a single physician to be managing the patient; depending on the location of the clot, it would be valuable to reach out to interventional radiology, surgery, neurology, or other specialties early on in the case. That additional disclaimer out of the way, let's move on to the actual management of a snake bitten patient who develops a significant thrombosis.

As I mentioned before, treatment will revolve around the balance between bleeding and clotting. The patient's risk of bleeding needs to be constantly evaluated and reevaluated, and the patient should be generously treated with antivenom for adequate venom neutralization. Of our three primary treatment modalities of thrombosis, we can essentially take thrombolytics off the table. Giving tPA to a patient at an elevated risk of hemorrhage is a potential death sentence and should rarely, if ever, be given. Thrombectomy, by contrast, should likely be pursued whenever indicated for these patients. Large-vessel stroke and massive pulmonary embolism both benefit from early thrombectomy, and while the patient will be at increased risk of bleeding from the puncture site in the groin used for vascular access, this can be managed with pressure, vascular closure devices, and if they are persistently coagulopathic, more antivenom. Unfortunately, the indications for thrombectomy are uncommon, which brings us to anticoagulation.

# Thick and Thin

Continued from page 5

Anticoagulating a patient after a snake envenomation is a difficult decision to make but can be done, and should at least be considered in any patient with thrombosis. The decision then must be made as to what anticoagulant should be chosen. The ideal anticoagulant would be one that can be quickly reversed in case the patient develops bleeding. The likely best choice is good old reliable heparin. Heparin is a potent anticoagulant with a short half-life, of about one hour, that is given as a continuous intravenous drip. This means that if the patient develops signs of bleeding, the drip can easily be switched off and the drug will wear off quickly. This process can be expedited further with a reversal agent called protamine sulfate which quickly inactivates heparin (fun fact, protamine sulfate is derived from salmon sperm, gross). In the stable patient who can receive heparin, it should be given as a drip until the envenomation has resolved and the patient can be transitioned over to a different anticoagulant that they can go home on. These patients will then require close follow-up due to the risk of recurrent coagulopathy, and should this occur, they will likely require readmission for more antivenom.

So, what have we seen? Over the last 22 years we have data on about 2000 envenomations, and we have had 6 patients develop clots, one of which went to the patient's lungs causing a PE, and one heart attack. We have also been contacted an additional 3 times regarding the development of a clot from providers who were practicing outside the AzPDIC's normal coverage area. We can then remark how rare these cases are, less than 1% of patients had any form of thrombosis after snake envenomation, and none of them became terribly sick from these clots, there were no cases of stroke or mesenteric ischemia. As for the heart attack, like I said before, there isn't a demonstrated link between heart disease and snake venom, so it's hard to say if the snake envenomation was really related to the patient's heart attack. Either way, the patient was treated with the usual therapy and did very well. Additionally, those DVTs and the PE all received some form of anticoagulation, heparin, low molecular weight heparin, warfarin, or a newer agent called rivaroxaban, and in all cases their clots resolved, none required any other interventions, and more importantly, none of them developed bleeding while on anticoagulants. This isn't a large enough sample size to make sweeping generalizations, but in the absence of other evidence, anticoagulants seem to be a reasonable treatment method for these patients.

To summarize, thrombosis in snake envenomation is rare but does occur, presenting one of the more challenging complications in toxicology, and one with very little research to back up therapy. Treatment of the thrombosis should coincide with antivenom. TPA should be avoided in envenomated patients. Anticoagulation can be used, with caution, and the agent used should be one that is easily reversible. Lastly, thrombectomy should be pursued when indicated. In all of this it is of the utmost importance to continue to monitor the patient's coagulation status, treat coagulopathies with antivenom, frequently reassess the patient for signs of occult bleeding, and have some specialists along for advice. For those of you who work in hospitals, I hope this patient never comes to you, but if it happens, don't hesitate to reach out to poison control at 1-800-222-1222.

